

Early Radiological Evaluation of Distal Radius Fractures Treated by Closed Reduction and Percutaneous Pinning in Adults Patients

Yetişkin Hastalarda Kapalı Redüksiyon ve Perkütan Pinleme ile Tedavi Edilen Distal Radius Kırıklarının Erken Radyolojik Değerlendirilmesi

© Mehmet Burak Yalçın, © Ahmed Heydar

Memorial Bahçelievler Hospital, Clinic of Orthopedics and Traumatology, İstanbul, Türkiye

ABSTRACT

Background: The use of closed reduction and percutaneous pinning in the treatment of distal radius fractures, both extra-articular and partial intra-articular, is a minimally invasive and cost-effective option that yields effective results. This study aimed to assess the radiological outcomes in adult patients, as well as to determine if the initial reduction is maintained over time and identify any demographic risk factors that may impact reduction loss.

Materials and Methods: Retrospective screening of patients with distal radius fracture treated by closed reduction and internal fixation in years between 2011 and 2020 yielded 47 adult patients with regular follow-up and accessible medical records. The included patients were divided into two groups according to their ages, 32 patients were under 60 years (group 1), and 14 were 60 years or older (group 2). Radiological assessment of radial height (Rh), radial inclination, ulnar variance, articular step, anteroposterior distance, palmar tilt, and teardrop angle in the posteroanterior and lateral radiographs obtained preoperatively, in the first follow-up (2 weeks) and when Kirschner (k) wires were removed (6-8 weeks) postoperatively. The measurements of both groups were statistically analyzed and compared.

Results: The mean age of patients was 52 (26-86) years and the mean period elapsed for K-wire removal was 6.5 (4-9) weeks. All radiological measurements showed improvement postoperatively in both groups. While the improved parameters were maintained in the third measurement of group 2 ($p>0.05$), the Rh of the third measurement in group 1 displayed a significant difference (0.78 mm) ($p=0.004$).

Conclusion: Percutaneous pinning can be an effective method for restoring radiographic parameters with minimal risk in appropriately selected fracture patterns. The good reproducible outcomes are not confined to young patients only but also can be utilized in elderly patients.

Keywords: Distal radius fracture, closed reduction, percutaneous pinning

ÖZ

Amaç: Hem eklem dışı hem de kısmi eklem içi distal radius kırıklarının tedavisinde kapalı redüksiyon ve perkütan çivilemenin kullanılması, etkili sonuçlar veren, minimal invaziv ve uygun maliyetli bir seçenektir. Bu çalışma yetişkin hastalarda radyolojik sonuçları değerlendirmeyi, başlangıçtaki redüksiyonun zaman içinde korunup korunmadığını belirlemeyi ve redüksiyon kaybını etkileyebilecek demografik risk faktörlerini tanımlamayı amaçladı.

Gereç ve Yöntemler: 2011-2020 yılları arasında kapalı redüksiyon ve internal tespit ile tedavi edilen distal radius kırığı olan hastaların retrospektif taranması sonucunda düzenli takipleri ve erişilebilir tıbbi kayıtları olan 47 yetişkin hasta çalışmaya dahil edildi. Hastalar yaşlarına göre iki gruba ayrıldı; 32 hasta 60 yaş altı (grup 1), 14 hasta ise 60 yaş ve üzerindedir (grup 2). Ameliyat öncesi, ilk takipte (2 hafta) ve ameliyat sonrası (6-8 hafta) Kirschner (k) telleri çıkarıldığında çekilen posteroanterior ve yan radyografilerde radial yükseklik, radial inklinasyon, ulnar varyans, eklemde basamaklanma, ön-arka mesafe, palmar eğim ve tear drop açısının radyolojik değerlendirilmesi yapıldı. Her iki grubun ölçümleri istatistiksel olarak analiz edildi ve karşılaştırıldı.

Bulgular: Hastaların ortalama yaşı 52 (26-86) yıl ve K telin çıkarılması için geçen süre ortalama 6,5 (4-9) haftaydı. Ameliyat sonrası tüm radyolojik ölçümlerde her iki grupta da iyileşme görüldü. Grup 2'de üçüncü ölçümde iyileşen parametreler korunurken ($p<0,05$), grup 1'de üçüncü ölçümde radial yükseklik anlamlı farklılık gösterdi (0,78 mm) ($p=0,004$).

Sonuç: Perkütan çivileme, uygun şekilde seçilmiş kırık modellerinde radyografik parametrelerin minimum riskle düzeltilmesinde etkili bir yöntem olabilir. Tekrarlanabilir iyi sonuçlar yalnızca genç hastalarla sınırlı değildir, aynı zamanda yaşlı hastalarda da kullanılabilir.

Anahtar Kelimeler: Distal radius kırığı, kapalı redüksiyon, perkütan çivileme



Address for Correspondence: Mehmet Burak Yalçın, Memorial Bahçelievler Hospital, Clinic of Orthopedics and Traumatology, İstanbul, Türkiye

Phone: +90 532 582 91 47 E-mail: mehmetburakyalcin@gmail.com **ORCID ID:** orcid.org/0000-0003-1016-452X

Received: 21.01.2024 **Accepted:** 14.02.2024



Copyright© 2024 The Author. Published by Galenos Publishing House on behalf of University of Health Sciences Türkiye, Hamidiye Faculty of Medicine. This is an open access article under the Creative Commons Attribution-NonCommercial-NoDerivatives 4.0 (CC BY-NC-ND) International License.

Introduction

One of the most frequent injuries to the upper extremities is a distal radius fracture. They exhibit a bimodal distribution with different characteristics. The first peak is seen in young patients with male predominance who most commonly sustained high-energy trauma, whereas elderly osteoporotic women who experienced low-energy trauma are the most common second peak representation (1). In this wide range of population, a large variety of fracture patterns can be distinguished, ranging from displaced comminuted intra-articular fractures to undisplaced simple extra-articular fractures. The diversity of fracture patterns merits different treatment options that also vary from non-operative treatment with closed reduction and cast immobilization to surgical intervention with the implementation of different devices such as Kirschner (k) wires, external fixators, different types of plates, and intramedullary nails (1,2).

Despite the recent tendency of trauma surgeons to internal fixation of radius fracture following the development of volar locking plates (3), complaints from tendon irritation and possible wound and fracture healing complications that may arise from extensive dissection of already injured soft tissue (3,4,5) disrupt the consensus on the ideal treatment of partial articular and extra-articular distal radius fracture (6), providing that there is no long-term outcome superiority of any fixation method to any other (7).

Closed reduction and percutaneous pinning (CRPP) of the distal radius are considered effective, minimally invasive, not technically demanding, and cost-effective treatment options for extra- and intra-articular fractures (8). The less invasive technique that prevents soft tissue damage and leaves no retained hardware tends to be more appealing because it avoids the complications that may arise from distal radius plating and achieves more biological osteosynthesis (8). The current study aimed to assess the radiological outcomes of extra-articular and partially intra-articular distal radius fractures in adult patients treated by CRPP, determine whether the initial reduction is maintained sufficiently, and identify the demographic risk factors that may affect the reduction loss.

Materials and Methods

Between 2011 and 2020, following the Medica International İstanbul Hospital Ethics Committee's approval of the study, the medical records of surgically operated distal radius fractures that were presented to our emergency department were identified and analyzed. The inclusion criteria were skeletally mature patients with an extra-articular or partial intra-articular fracture of the distal

radius (AO type 23-A2, A3 and 23-C1, C2) who were treated with CRPP. Regular postoperative follow-up for a minimum of 6-8 weeks and accessibility to medical records are required for patient inclusion. Cases with open epiphysis, concomitant fracture of the affected limb, and pathologic fractures were excluded.

The medical records of 624 adult patients with distal radius fractures admitted to our hospital were reviewed; 52 of them had extra-articular or partial intra-articular fractures that were treated with CRPP. However, 6 patients were excluded because of the inaccessibility of medical records and loss of follow-up. To evaluate the effect of age and osteoporosis on reduction loss based on age 60 years. The 47 patients with 47 wrist fractures (Table 1) were grouped according to their age into two groups: 32 patients were under 60 years of age (group 1) and 14 were 60 years or older (group 2). Radiological imaging was used to confirm the union and to compare both groups concerning any loss of reduction.

Conventional radiographs with posterior-anterior and lateral views were used for diagnosing and regularly following up with the patients. Radiologic measurement of radial height (Rh), palmar tilt (Pt), radial inclination (Ri), ulnar variance (Uv), articular step (As), anteroposterior distance (Apd), and teardrop angle (Tda) of the images taken in the preoperative, first follow-up, and last follow-up settings. The first follow-up visits were within 2 weeks of the operation, whereas the last follow-up visits were 6 to 8 weeks after the surgery when the K-wires were removed. All parameters were measured separately by two board-certified orthopedic surgeons, and any discrepancy was resolved by accepting the mean value. The measurements were then statistically analyzed and compared.

Surgical Technique

Under general anesthesia or axillary block following surgical preparation and draping, closed reduction was performed by applying longitudinal traction to disimpact the fracture fragments and direct manipulation by flexing or extending the distal fragment with ulnar deviation according to the displacement pattern. The reduction was assessed by fluoroscopic examination, and in cases where the anatomic reduction could not be achieved, CRPP was performed. Following fluoroscopic verification of anatomical reduction, a small stab incision with blunt dissection through the subcutaneous tissue to the tip of the radial styloid was performed before K-wire placement to minimize tendon and nerve injury. The first K-wire was introduced retrogradely using a soft tissue protector from the tip of the styloid process crossing the fracture site to engage the medial cortex of the proximal fragment. A second K-wire was placed in the



same manner but in a divergent projection. In intra-articular distal radius fractures, a third K-wire was placed. Before its insertion another stab incision and blunt dissection were made to expose the dorsoulnar corner of the radius. The wire was placed under fluoroscopic guidance, crossing the fracture and penetrating the proximal fragment cortex volarly, creating a cross-shaped configuration with the other K-wires. According to the morphology of the fracture, extra wires could be placed to secure the fracture fragments and augment the stability. After confirming the position of the wires, they were cut and the ends bent, and dressing and a

well-padded short arm cast were applied. For pin site care, windows in the cast directly over the pin site were created.

Postoperative Care

The patients were discharged on the same or the next day of the operation. The physical examination was routinely performed in the 2nd, 4th, and 6th to 8th week. Radiological assessment was performed during the first and last follow-up visits (Figures 1, 2). K-wires were removed in outpatient settings during the sixth to eighth week when clinical and radiological fracture union was achieved. Fracture union was defined by the absence of tenderness over the fracture

Table 1. Demographic data of the patients

	n	%				
Age						
<60	33	70.2%				
>60	14	29.8%				
Gender						
Female	34	72.3%				
Male	13	27.7%				
Side						
Right	23	48.9%				
Left	24	51.1%				
AO muller						
A2	7	14.9%				
A3	17	36.2%				
C1	16	34.0%				
C2	7	14.9%				
Additional fracture						
No	44	93.6%				
Yes	3	6.4%				
Complication						
No	37	78.7%				
Yes	10	21.3%				
Trauma						
Simple fall	43	91.5%				
Traffic accident	2	4.3%				
Fall*	1	2.1%				
Falling from the ladder	1	2.1%				
	Mean ± SD	Min	Q1	Q2	Q3	Max
Age/years	52.11±13.58	26	42	54	61	86
Number of K-wires	2.77±1.11	2	2	2	3	7
Remove of K-wires/week	6.34±1.05	4	6	6	7	9
Days from trauma to surgery/day	1.55±2.51	0	0	1	2	14
*Operated 2 weeks later because of open fracture SD: Standard deviation, Min: Minimum, Max: Maximum, Q1: Percentile 25, Q2: Percentile 50 (Median), Q3: Percentile 75, K-wires: Kirschner wires						

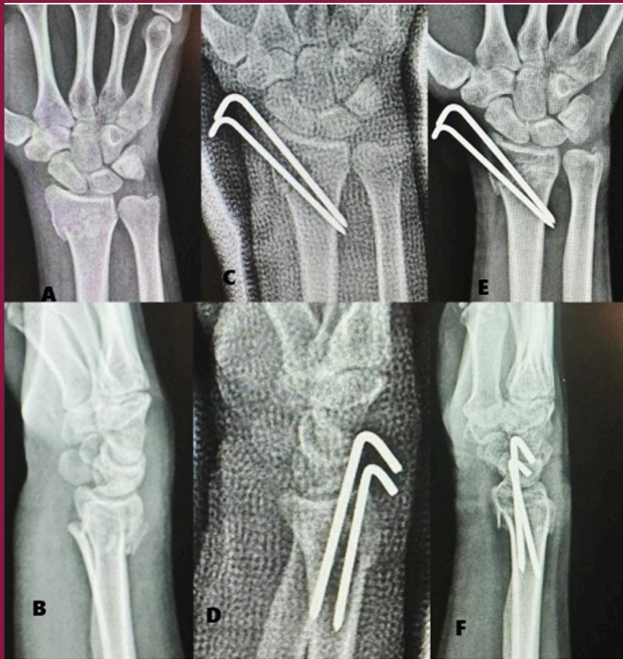

Figure 1. A 27-year-old female patient. A/B: Preoperative, C/D: After 2 weeks of operation, E/F: After 6 weeks of operation Pa and Lateral wrist X-ray

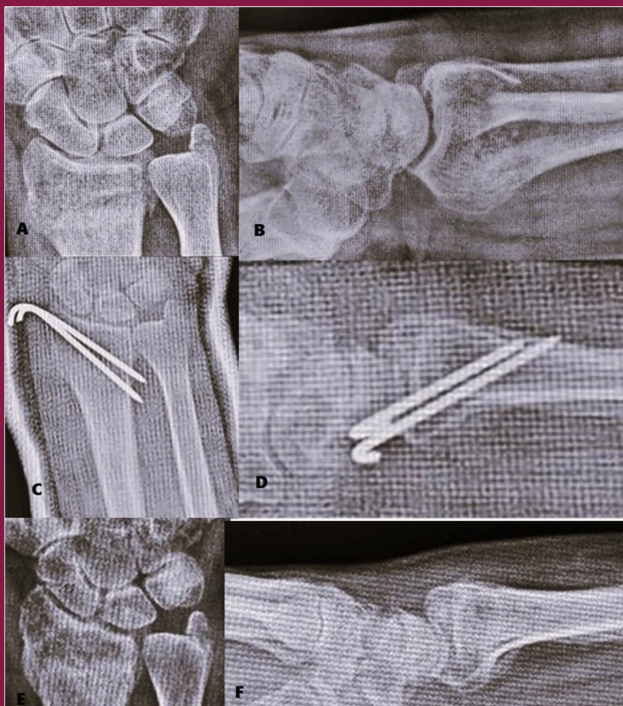


Figure 2. A 62-year-old female patient. A/B: Preoperative, C/D: After 2 weeks of operation, E/F: After 8 weeks of operation Pa and Lateral wrist X-ray

site and the presence of a bridging callus on X-ray. After K-wire removal, patients with limited range of motions were referred to the physical therapy department.

Statistical Analysis

The SPSS 26.0 program and PAST 3 software were used to analyze the study variables. To evaluate the conformity of univariate data to a normal distribution, we employed the Kolmogorov-Smirnov and Shapiro-Wilk tests. In addition, we used the to assess the homogeneity of variance. For multivariate data, we conducted the Mardia test for normal distribution, the Dornik and Hansen omnibus test, and the Box-M test for homogeneity of variance. When comparing two independent groups based on quantitative data, we used the independent samples t-test with bootstrap results and the Mann-Whitney U test with Monte Carlo results. When comparing more than two groups, we used One-Way analysis of variance (ANOVA), a parametric method, and Fisher's least significant difference (LSD) tests for post hoc analyses. Alternatively, we employed the Kruskal-Wallis H test, a non-parametric test, along with the results from the Monte Carlo simulation technique and Dunn's test for post hoc analyses. When conducting post hoc analysis to compare multiple repeated measurements of dependent quantitative variables and examine their interaction according to groups, the General Linear Model-Repeated ANOVA test and Fisher's LSD tests were used. For non-parametric methods, Friedman's two-way test and stepwise post hoc test, which involved step-down comparisons, were used. In evaluating categorical variables, Pearson's chi-square and Fisher's Exact tests were employed, with exact results used for the Fisher's Exact test. The Fisher-Freeman-Holton test was performed using the Monte Carlo simulation technique, and column ratios were compared and expressed in terms of the Benjamini-Hochberg-corrected p-value results. The presentation of quantitative variables included the mean \pm standard deviation in the tables, and the median (percentile 25/percentile 73). Categorical variables are displayed as n (%). The analysis was conducted at a 95% confidence level, and a p-value <0.05 was considered significant.

Results

The mean age of the patients was 52 (26-86) years, and the mean period elapsed for K-wire removal was 6.5 (4-9) weeks. Radiological evaluation showed improvement in Rh, Ri, Uv, As, Pt, Apd, and Tda parameters in all patients postoperatively, and this improvement was maintained at the time of K-wire removal in group 2. The mean values of these parameters are shown in Table 2.

In group 1 patients, no significant difference was detected in Ri, Uv, As, Pt, Apd, and Tda values between the

Table 2. Average values of radiological measurements made 1) before surgery, 2) 2 weeks after surgery, and 3) 6-8 weeks after surgery

	1 (preoperative)	2 (2 nd week)	3 (6-8 th week)
Radial height (mm)	8.85±2.24	10.84±1.31	10.12±1.40
Radial inclination degrees	15.87±6.34	20.00±2.82	19.85±3.88
Ulnar variance (mm)	2.09±3.24	0.49±1.90	1.06±1.94
Articular step (mm)	0.17±0.76	0.04±0.53	0.09±0.39
Anteroposterior distance (mm)	17.77±7.6	18.66±2.98	18.08±2.72
Palmar tilt, degrees	-17.84±16.12	9.84±7.36	9.45±9.59
Teardrop angle, degrees	19.58±23.46	43.8±9.15	41.13±8.20

3rd and 2nd measurements, yet a significant difference was detected in Rh values between these measurements (0.004) ($p < 0.05$). All values are shown in Table 3.

Discussion

In the current study, we evaluated the role of K-wires in sustaining the reduction of extra-articular or partial articular distal radius fracture in adults treated with CRPP. Our results showed that CRPP is an effective technique for restoring and sustaining radiologic parameters during the healing process regardless of patient demographic criteria and fracture pattern (AO type 23-A2, A3 and 23-C1, C2).

Several clinical and biomechanical studies have highlighted the significance of ensuring an articular gap of 2 mm and maintaining optimal Pt, Uv, and Rh in achieving favorable patient outcomes (9). Failure to meet and maintain these objectives during fracture reduction and the osseous union process suggests that non-surgical management could not obtain the intended outcomes. Lafontaine et al. (10) defined unstable fractures and identified risk factors for loss of initial reduction with non-operative treatment, which was verified by other studies (11). The predictors for loss of reduction were intra-articular fracture, dorsal comminution dorsal angulation more than 20 degrees, concomitant ulnar fractures, and age older than 60 years. The indication for surgical intervention in our study was largely based on these predictors, which estimate a low possibility of successful non-surgical management.

Although there is a substantial amount of research on the surgical management of distal radius fractures, only limited evidence-based recommendations are available for surgeons in selecting a fixation method (12). Many surgeons prefer CRPP because of its practicality, minimal morbidity, and low complication rate in treating extra-articular and partial intra-articular fractures with minimal reducible As (13). However, advances in biomedical hardware manufacturing have shifted the tendency to treat distal radius fractures from CRPP to open reduction and internal fixation (ORIF) (12). However, the long-term results of many

studies showed no superiority of ORIF over CRPP (14,15). Thus, CRPP was the mainstay of treatment for these specific distal radius fractures in our institution.

Successful management of distal radius fracture is not based only on the achievement of anatomical reduction but also on its maintenance until bone healing is ensured. Unstable non-displaced fractures, especially those that require initial reduction, are at great risk of redisplacement (16). Loss of reduction develops most frequently in the second week of non-operative management (17). Percutaneous pinning has been criticized for its inability to maintain the initial postoperative reduction and for allowing the fracture to subside during the healing process (18). Conversely, we demonstrated that all patients treated with CRPP had preserved initial reduction in the second week of follow-up and until osseous union had been achieved.

The most important finding in our study demonstrates that percutaneous pinning provides good radiological outcomes in elderly patients over 60 years of age who have extra-articular or partially intra-articular distal radius fractures. Previous studies have shown that this technique has less favorable results in elderly patients (19); even some authors considered these fractures a contraindication to CRPP (20) provided that previous studies in elderly patients had a considerable rate of secondary instability after pinning fixation (21,22). Furthermore, Azzopardi et al. (19) showed only a marginal improvement in the radiological parameters in patients aged over 60 years with extra-articular distal radius fractures compared with non-operative treatment. In contrast, our results reported good radiological outcomes in patients older than 60 years, comparable to the outcomes of younger patients. These results were consistent with those of some other prior studies despite their age heterogeneity (12) and application of different pinning techniques (23).

The relationship between radiological and functional outcomes is a topic of debate. Despite many studies demonstrating a significant functional deficiency in the elderly who presented with malunited distal radius fractures (23,24,25), other studies could not find any relationship between radiological and functional outcomes (19,26).

Table 3. Comparison of mean radiological parameter values in patients under and over 60 years of age

Age			
	<60 (A)	>60 (B)	p-value
	(n=33)	(n=14)	(A-B)
	Median	Median	
Ri			
1	16.0	17.5	0.358
2	20.0	21.0	0.166
3	20.0	19.5	0.802
Diference 3-2	0.0	-2.0	0.285
P-value 3-2	0.999	0.999	-
Uv			
1	1.8	2.9	0.537
2	0.0	1.0	0.261
3	0.0	1.6	0.215
Diference 3-2	0.0	0.4	0.354
P-value 3-2	0.196	0.073	-
As			
1	0.0	0.3	0.034
2	0.0	0.0	0.788
3	0.0	0.0	0.147
Diference 3-2	0.0.	0.0	0.999
P-value 3-2	Ns.	Ns.	-
Apd			
1	17.8	19.6	0.024
2	17.8	18.5	0.093
3	17.6	18.0	0.085
Diference 3-2	-0.2	-0.4	0.646
P-value 3-2	Ns.	Ns.	-
Pt			
1	-24.0	-8.5	0.084
2	11.0	11.0	0.899
3	10.5	11.8	0.458
Diference 3-2	-0.1	0.0	0.899
P-value 3-2	0.622	0.705	-
Rh			
1	8.56	9.54	0.204
2	10.72	11.14	0.351
3	9.93	10.59	0.128
Diference 3-2	-0.78	-0.55	0.654
P-value 3-2	0.004	Ns.	-
Tda			
1	18.11	23.07	0.501
2	43.18	45.29	0.482
3	40.75	41.94	0.746
Diference 3-2	-2.43	-3.35	0.701
P-value 3-2	0.057	0.126	-

Patients under the age of 60 years were shown as group A, and patients aged 60 and over were shown as group B. Statistical significance values of columns A-B are written in the p-value (A-B) column. In the p-value 3-2 line, statistical significance values between the 3rd and 2nd measurements are given.

Ns.: Not significant, Ri: Radial inclination, Uv: Ulnar variance, As: Articular step, Apd: Anteroposterior distance, Pt: Palmar tilt, Rh: Radial height, Tda: Teardrop angle

In our opinion, anatomical reduction and acceptable radiological parameters are strongly associated with better functional outcomes not only in young patients but also in elderly patients. This was the reason for performing surgical intervention with percutaneous pinning instead of non-operative treatment in elderly patients.

K-wire placement may accompany the different types of nerve and tendon injuries. Dorsally positioned K-wires are generally favored over volar-placed wires because of the potential danger of injury to the neurovascular structures and flexor tendons of the digits. However, several structures are at risk of being injured by dorsally placed K-wires. Cadaveric dissection showed that the extensor tendons of the digit and the superficial branch of the radial nerve were at the highest risk of injury (27). A tiny incision extending through subcutaneous tissue to the bone and the use of soft tissue protectors were adopted to avoid inadvertent injury during pinning. We believe that these measures were the reason for not encountering such complications in our cohort. The only complication that we encountered was a pin tract infection that was treated by systemic antibiotics and pin site care. All of these infections were resolved following pin removal.

Study Limitations

The retrospective nature of the study, short-term follow-up, and small number of patients may represent the main limitations of the current study. A prospective, randomized trial with a longer follow-up period and a larger patient population is needed for the evaluation of K-wire long-term radiological outcomes and its association with clinical and functional outcomes. The current study is designed to highlight the effectiveness of CRPP for treating elderly patients with specific types of distal radius fractures and to form a base for further studies directed toward standardization of treatment.

Conclusion

Percutaneous pinning can be an effective method for restoring radiographic parameters with minimal risk in properly selected fracture patterns. The good reproducible outcomes are not confined to young patients only; elderly patients can also be treated successfully by CRPP. This method can offer sufficient fracture stability, the lowest complication rate, and low patient morbidity, which, in contrast to more invasive treatments, may provide a faster functional recovery.

Ethics

Ethics Committee Approval: Between 2011 and 2020, following the Medicana International İstanbul Hospital

Ethics Committee's approval of the study, the medical records of surgically operated distal radius fractures that were presented to our emergency department were identified and analyzed.

Informed Consent: Retrospectively study.

Authorship Contributions

Surgical and Medical Practices: M.B.Y., Concept: M.B.Y., A.H., Design: M.B.Y., A.H., Data Collection or Processing: M.B.Y., A.H., Analysis or Interpretation: M.B.Y., A.H., Literature Search: M.B.Y., A.H., Writing: M.B.Y., A.H.

Conflict of Interest: No conflict of interest was declared by the authors.

Financial Disclosure: The authors declared that this study received no financial support.

References

1. Meaike JJ, Kakar S. Management of Comminuted Distal Radius Fractures: A Critical Analysis Review. *JBJS Rev.* 2020;8:e2000010. [[Crossref](#)]
2. Gradl G, Mielsch N, Wendt M, Falk S, Mittlmeier T, Gierer P, et al. Intramedullary nail versus volar plate fixation of extra-articular distal radius fractures. Two year results of a prospective randomized trial. *Injury.* 2014;45(Suppl 1):S3-8. [[Crossref](#)]
3. Downing ND, Karantana A. A revolution in the management of fractures of the distal radius? *J Bone Joint Surg Br.* 2008;90:1271-1275. [[Crossref](#)]
4. Leversedge FJ, Srinivasan RC. Management of soft-tissue injuries in distal radius fractures. *Hand Clin.* 2012;28:225-233. [[Crossref](#)]
5. Mandziak DG, Watts AC, Bain GI. Ligament contribution to patterns of articular fractures of the distal radius. *J Hand Surg Am.* 2011;36:1621-1625. [[Crossref](#)]
6. Van Oijen GW, Van Lieshout EMM, Reijnders MRL, Appalsamy A, Hagenaars T, Verhofstad MHJ. Treatment options in extra-articular distal radius fractures: a systematic review and meta-analysis. *Eur J Trauma Emerg Surg.* 2022;48:4333-4348. [[Crossref](#)]
7. Leixnering M, Rosenauer R, Pezzeri C, Jurkowsitch J, Beer T, Keuchel T, et al. Indications, surgical approach, reduction, and stabilization techniques of distal radius fractures. *Arch Orthop Trauma Surg.* 2020;140:611-621. [[Crossref](#)]
8. Glickel SZ, Catalano LW, Raia FJ, Barron OA, Grabow R, Chia B. Long-term outcomes of closed reduction and percutaneous pinning for the treatment of distal radius fractures. *J Hand Surg Am.* 2008;33:1700-1705. [[Crossref](#)]
9. Gofton W, Liew A. Distal Radius Fractures: Nonoperative and Percutaneous Pinning Treatment Options. *Orthop Clin North Am.* 2007;38:175-185. [[Crossref](#)]
10. Lafontaine M, Hardy D, Delince PH. Stability assessment of distal radius fractures. *Injury.* 1989;20:208-210. [[Crossref](#)]
11. LaMartina J, Jawa A, Stucken C, Merlin G, Tornetta P. Predicting alignment after closed reduction and casting of distal radius fractures. *J Hand Surg Am.* 2015;40:934-939. [[Crossref](#)]
12. Özkan S, Westenberg RF, Helliwell LA, Mudgal CS. Distal Radius Fractures: Evaluation of Closed Reduction and Percutaneous Kirschner Wire Pinning. *J Hand Microsurg.* 2018;10:134-138. [[Crossref](#)]
13. Gottschalk MB, Wagner ER. Kirschner Wire Fixation of Distal Radius Fractures, Indication, Technique and Outcomes. *Hand Clin.* 2021;37:247-258. [[Crossref](#)]
14. Koval KJ, Harrast JJ, Anglen JO, Weinstein JN. Fractures of the distal part of the radius. The evolution of practice over time. Where's the evidence? *J Bone Joint Surg Am.* 2008;90:1855-1861. [[Crossref](#)]

15. Dzaja I, MacDermid JC, Roth J, Grewal R. Functional outcomes and cost estimation for extra-articular and simple intra-articular distal radius fractures treated with open reduction and internal fixation versus closed reduction and percutaneous Kirschner wire fixation. *Can J Surg.* 2013;56:378-384. [\[Crossref\]](#)
16. Leone J, Bhandari M, Adili A, McKenzie S, Moro JK, Dunlop RB. Predictors of early and late instability following conservative treatment of extra-articular distal radius fractures. *Arch Orthop Trauma Surg.* 2004;124:38-41. [\[Crossref\]](#)
17. Altissimi M, Mancini GB, Azzarà A, Ciaffoloni E. Early and late displacement of fractures of the distal radius. The prediction of instability. *Int Orthop.* 1994;18:61-65. [\[Crossref\]](#)
18. Barton T, Chambers C, Lane E, Bannister G. Do Kirschner wires maintain reduction of displaced Colles' fractures? *Injury.* 2005;36:1431-1434. [\[Crossref\]](#)
19. Azzopardi T, Ehrendorfer S, Coulton T, Abela M. Unstable extra-articular fractures of the distal radius: a prospective, randomised study of immobilisation in a cast versus supplementary percutaneous pinning. *J Bone Joint Surg Br.* 2005;87:837-840. [\[Crossref\]](#)
20. Simic PM, Weiland AJ. Fractures of the distal aspect of the radius: changes in treatment over the past two decades. *Instr Course Lect.* 2003;52:185-195. [\[Crossref\]](#)
21. Lenoble E, Dumontier C, Goutallier D, Apoil A. Fracture of the distal radius. A prospective comparison between trans-styloid and Kapandji fixations. *J Bone Joint Surg Br.* 1995;77:562-567. [\[Crossref\]](#)
22. Mah ET, Atkinson RN. Percutaneous Kirschner wire stabilisation following closed reduction of Colles' fractures. *J Hand Surg Br.* 1992;17:55-62. [\[Crossref\]](#)
23. Board T, Kocalkowski A, Andrew G. Does Kapandji wiring help in older patients? A retrospective comparative review of displaced intra-articular distal radial fractures in patients over 55 years. *Injury.* 1999;30:663-669. [\[Crossref\]](#)
24. McQueen M, Caspers J. Colles fracture: does the anatomical result affect the final function? *J Bone Joint Surg Br.* 1988;70:649-651. [\[Crossref\]](#)
25. Fujii K, Henmi T, Kanematsu Y, Mishiro T, Sakai T, Terai T. Fractures of the distal end of radius in elderly patients: a comparative study of anatomical and functional results. *J Orthop Surg (Hong Kong).* 2002;10:9-15. [\[Crossref\]](#)
26. Synn AJ, Makhni EC, Makhni MC, Rozental TD, Day CS. Distal radius fractures in older patients: is anatomic reduction necessary? *Clin Orthop Relat Res.* 2009;467:1612-1620. [\[Crossref\]](#)
27. Santoshi JA, Chaware PN, Pakhare AP, Rathinam BAD. An Anatomical Study to Demonstrate the Proximity of Kirschner Wires to Structures at Risk in Percutaneous Pinning of Distal Radius Fractures. *J Hand Microsurg.* 2015;7:73-78. [\[Crossref\]](#)